

Neurologic Involvement in Children and Adolescents Hospitalized in the United States for COVID-19 or Multisystem Inflammatory Syndrome

Kerri L. LaRovere, MD; Becky J. Riggs, MD; Tina Y. Poussaint, MD; Cameron C. Young; Margaret M. Newhams, MPH; Mia Maamari, MD; Tracie C. Walker, MD; Aalok R. Singh, MD; Heda Dapul, MD; Charlotte V. Hobbs, MD; Gwenn E. McLaughlin, MD; Mary Beth F. Son, MD; Aline B. Maddux, MD; Katharine N. Clouser, MD; Courtney M. Rowan, MD; John K. McGuire, MD; Julie C. Fitzgerald, MD, PhD; Shira J. Gertz, MD; Steven L. Shein, MD; Alvaro Coronado Munoz, MD; Neal J. Thomas, MD; Katherine Irby, MD; Emily R. Levy, MD; Mary A. Staat, MD; Mark W. Tenforde, MD, PhD; Leora R. Feldstein, PhD; Natasha B. Halasa, MD, MPH; John S. Giuliano Jr, MD; Mark W. Hall, MD; Michele Kong, MD; Christopher L. Carroll, MD; Jennifer E. Schuster, MD; Sule Doymaz, MD; Laura L. Loftis, MD; Keiko M. Tarquinio, MD; Christopher J. Babbitt, MD; Ryan A. Nofziger, MD; Lawrence C. Kleinman, MD, MPH; Michael A. Keenaghan, MD; Natalie Z. Cvijanovich, MD; Philip C. Spinella, MD; Janet R. Hume, MD, PhD; Kari Wellnitz, MD; Elizabeth H. Mack, MD; Kelly N. Michelson, MD; Heidi R. Flori, MD; Manish M. Patel, MD; Adrienne G. Randolph, MD; for the Overcoming COVID-19 Investigators

 Supplemental content

IMPORTANCE Coronavirus disease 2019 (COVID-19) affects the nervous system in adult patients. The spectrum of neurologic involvement in children and adolescents is unclear.

OBJECTIVE To understand the range and severity of neurologic involvement among children and adolescents associated with COVID-19.

SETTING, DESIGN, AND PARTICIPANTS Case series of patients (age <21 years) hospitalized between March 15, 2020, and December 15, 2020, with positive severe acute respiratory syndrome coronavirus 2 test result (reverse transcriptase-polymerase chain reaction and/or antibody) at 61 US hospitals in the Overcoming COVID-19 public health registry, including 616 (36%) meeting criteria for multisystem inflammatory syndrome in children. Patients with neurologic involvement had acute neurologic signs, symptoms, or diseases on presentation or during hospitalization. Life-threatening involvement was adjudicated by experts based on clinical and/or neuroradiologic features.

EXPOSURES Severe acute respiratory syndrome coronavirus 2.

MAIN OUTCOMES AND MEASURES Type and severity of neurologic involvement, laboratory and imaging data, and outcomes (death or survival with new neurologic deficits) at hospital discharge.

RESULTS Of 1695 patients (909 [54%] male; median [interquartile range] age, 9.1 [2.4-15.3] years), 365 (22%) from 52 sites had documented neurologic involvement. Patients with neurologic involvement were more likely to have underlying neurologic disorders (81 of 365 [22%]) compared with those without (113 of 1330 [8%]), but a similar number were previously healthy (195 [53%] vs 723 [54%]) and met criteria for multisystem inflammatory syndrome in children (126 [35%] vs 490 [37%]). Among those with neurologic involvement, 322 (88%) had transient symptoms and survived, and 43 (12%) developed life-threatening conditions clinically adjudicated to be associated with COVID-19, including severe encephalopathy (n = 15; 5 with splenic lesions), stroke (n = 12), central nervous system infection/demyelination (n = 8), Guillain-Barré syndrome/variants (n = 4), and acute fulminant cerebral edema (n = 4). Compared with those without life-threatening conditions (n = 322), those with life-threatening neurologic conditions had higher neutrophil-to-lymphocyte ratios (median, 12.2 vs 4.4) and higher reported frequency of D-dimer greater than 3 µg/mL fibrinogen equivalent units (21 [49%] vs 72 [22%]). Of 43 patients who developed COVID-19-related life-threatening neurologic involvement, 17 survivors (40%) had new neurologic deficits at hospital discharge, and 11 patients (26%) died.

CONCLUSIONS AND RELEVANCE In this study, many children and adolescents hospitalized for COVID-19 or multisystem inflammatory syndrome in children had neurologic involvement, mostly transient symptoms. A range of life-threatening and fatal neurologic conditions associated with COVID-19 infrequently occurred. Effects on long-term neurodevelopmental outcomes are unknown.

JAMA Neurol. doi:10.1001/jamaneurol.2021.0504
Published online March 5, 2021.

Author Affiliations: Author affiliations are listed at the end of this article.

Group Information: A list of additional members of the Overcoming COVID-19 Investigators are listed in [Supplement 2](#).

Corresponding Author: Adrienne G. Randolph, MD, Boston Children's Hospital, 300 Longwood Ave, Bader 634, Boston, MA 02115 (adrienne.randolph@childrens.harvard.edu).

Coronaviruses primarily cause respiratory disease; however, severe acute respiratory syndrome coronavirus (SARS-CoV), Middle East respiratory syndrome coronavirus, and newly identified SARS-CoV-2 have been associated with a range of disorders of the peripheral and central nervous system (CNS).¹⁻⁹ Early reports from Wuhan, China, described a spectrum of neurologic conditions associated with SARS-CoV-2 infection in 36% of 214 adults hospitalized with coronavirus disease 2019 (COVID-19).¹⁰ Reported neurologic and psychiatric symptoms in adult patients with COVID-19 include anosmia/ageusia,^{11,12} headaches,¹³ dizziness/ataxia,¹⁰ psychosis, dementia, depression, anxiety, and mania.¹⁴ Reported severe neurologic involvement in adult patients with COVID-19 includes acute encephalopathy or encephalitis,¹⁵⁻¹⁸ acute necrotizing encephalopathy,^{19,20} epilepsy/seizures,^{21,22} acute transverse myelitis,²³⁻²⁵ Guillain-Barré syndrome (GBS),^{26,27} posterior reversible encephalopathy syndrome,²⁸ and acute ischemic or hemorrhagic stroke.^{14,29-34}

Although most children and adolescents are spared from severe COVID-19, there have been reports of life-threatening neurologic involvement in patients developing multisystem inflammatory syndrome in children (MIS-C), a relatively rare, hyperinflammatory, severe illness temporally associated with SARS-CoV-2 infection, presumably postinfectious.^{35,36} Across case series published between March and August 14, 2020, between 6% and 58% of children and adolescents hospitalized with MIS-C developed central and/or peripheral nervous system involvement.³⁶⁻⁴⁰ The frequency of neurologic involvement in children hospitalized with acute COVID-19 is unclear with 150 of 4190 patients reported across 9 international case series.⁴¹⁻⁴⁶ Using the Overcoming COVID-19 US public health surveillance registry of children and adolescents hospitalized with COVID-19-related complications,³⁶ we aimed to describe the type and severity of neurologic involvement and documented hospital outcomes.

Methods

Study Design and Participants

Active surveillance was performed at 61 hospitals in 31 states in the Overcoming COVID-19 network to identify children and adolescents (age <21 years) with SARS-CoV-2-related illness hospitalized from March 15, 2020, to December 15, 2020. The study was approved by the central institutional review board at Boston Children's Hospital and determined to meet the requirement of public health surveillance as defined in 45 CFR 46.102(I)(2) at Boston Children's Hospital and the US Centers for Disease Control and Prevention under a waiver of consent.

Patients were included if they were hospitalized for acute illness at a participating site, were younger than 21 years, had a positive SARS-CoV-2 test result (reverse transcriptase-polymerase chain reaction and/or antibody) and symptoms associated with acute COVID-19, or met US Centers for Disease Control and Prevention criteria for MIS-C (eTable 1 in Supplement 1).⁴⁷ Patients were excluded if they had asymptomatic SARS-CoV-2 infection or a non-COVID-19-related cause

Key Points

Question What is the extent of neurologic involvement in US hospitalized children and adolescents with coronavirus disease 2019 (COVID-19)?

Findings In this study of 1695 patients 21 years or younger hospitalized for acute COVID-19 or multisystem inflammatory syndrome, 365 (22%) had neurologic involvement. Forty-three patients (12%) developed COVID-19-related life-threatening neurologic disorders, 11 (26%) died, and 17 (40%) survived with new neurologic sequelae.

Meaning In this study, COVID-19-related neurologic involvement was common in hospitalized children and adolescents and mostly transient.

for hospitalization or death. Race and ethnicity were extracted from the patient's medical record and included to evaluate risk of neurologic involvement.

Classification of Neurologic Involvement

Patients were stratified by the presence of neurologic involvement, defined as (1) suspected acute neurologic disease (eg, CNS infection/demyelination or stroke) on presentation or that developed during hospitalization (eMethods in Supplement 1) or (2) acute neurologic signs or symptoms on presentation.

Severity of neurologic involvement was adjudicated by neurology and critical care experts on the central study team (K.L.L., B.J.R., T.Y.P., and A.G.R.; eMethods in Supplement 1). Cases were classified as life-threatening based on clinical and/or neuroradiologic features associated with more severe outcomes and included the following diagnoses: acute CNS infection (aseptic meningitis, encephalitis by International Encephalitis Consortium definition,⁴⁸ and Brighton criteria⁴⁹), central demyelinating disorder (acute disseminated encephalomyelitis [ADEM]), acute ischemic or hemorrhagic stroke, GBS and variants, or severe encephalopathy with or without COVID-19-related neuroimaging abnormalities (eg, virus-associated necrotizing disseminated acute leukoencephalopathy⁵⁰ and/or cytotoxic splenic lesions^{44,51,52}). Cases with neurologic involvement that did not meet any of these criteria and had cerebrospinal fluid and/or neuroimaging results that were normal or not performed were categorized as non-life-threatening neurologic involvement.

Neurologic Outcome Classification

Neurology and critical care experts (K.L.L., B.J.R., and A.G.R.) determined through case review and consensus whether life-threatening neurologic conditions were directly associated with COVID-19 or secondary to exacerbation of primary neurologic disease or complication of critical illness associated with COVID-19. Sites with abnormal neuroimaging studies sent deidentified brain magnetic resonance imaging (MRI) and computed tomography studies for central review. Images were reviewed by a pediatric neuroradiologist (T.Y.P.) and discussed with a pediatric neurologist (K.L.L.) reaching consensus opinion about whether the clinicroadiologic link was directly associated with COVID-19 or secondary to an alternate etiology

(eg, extracorporeal membrane oxygenation [ECMO] or preexisting neurologic condition).

Outcomes were determined at hospital discharge. Neurologic deficits were defined as gross impairment in motor, cognitive, or speech and language functions. Psychiatric sequelae (eg, anxiety, depression, and/or suicidal ideation) were not included. New neurologic deficits were determined by medical record review at each site and adjudicated by the experts for all patients with and without neurologic involvement (eMethods in Supplement 1).

Statistical Analyses

We report the frequency of clinical characteristics, underlying conditions, type of neurologic involvement on admission or during hospitalization, and hospital outcomes. Continuous variables were expressed as medians and interquartile range. Categorical variables were expressed as counts and percentages. Between-group differences were analyzed using a χ^2 test, Fisher exact test, or Kruskal-Wallis test where appropriate. Two-sided *P* values less than .05 were considered statistically significant. We did not impute missing data. We analyzed all data using R software, version 3.6.1 (R Project for Statistical Computing).

Results

Demographics and Clinical Characteristics Among All Patients

From March 15, 2020, to December 15, 2020, a total of 1784 hospitalized children and adolescents with COVID-19-related illness were reported to the registry. Of these, 89 patients were excluded on the basis of being 21 years or older (*n* = 27), epidemiologic link to SARS-CoV-2 without a positive test result (*n* = 54), and non-COVID-19-related cause for hospitalization or death (*n* = 8) (eFigure in Supplement 1). We describe 1695 patients (909 male [54%]; median [interquartile range] age, 9.1 [2.4-15.3] years) from 61 sites in 31 states (Table 1). Most patients were either Hispanic or Latino (638 of 1695 [38%]) or non-Hispanic Black (442 of 1695 [26%]).

Neurologic vs Nonneurologic Involvement

There were 365 patients (22%) with neurologic involvement reported from 52 sites in 29 states. The characteristics of the patients with and without neurologic involvement are shown in Table 1. The frequencies of previously healthy patients (195 [53%] vs 723 [54%]) and patients meeting MIS-C criteria (126 [35%] vs 490 [37%]) were similar. Patients with neurologic involvement were more likely to have underlying neurologic disorders (81 [22%]) compared with those without (113 [8%]), including seizure disorders, neuromuscular disorders, and autism or developmental delay. Presenting neurologic signs and symptoms differed by age with seizures or status epilepticus most common in children younger than 5 years and anosmia and/or ageusia most common in patients between ages 13 and 20 years (Figure 1A).

Most patients with and without neurologic involvement were discharged alive (351 [96%] and 1322 [99%], respec-

tively). Children with neurologic involvement had a higher rate of survival with new neurologic deficits (20 of 365 [5%]) compared with those without COVID-19-associated neurologic involvement (2 of 1330 [0.2%]) (Table 1). Neurologic deficits in those without neurologic involvement included cognitive and motor impairments as a result of sequelae of critical illness and intensive care therapies.

Life-threatening Neurologic Involvement

Among 365 patients with neurologic involvement, 43 (12%) had life-threatening neurologic involvement associated with COVID-19 (Table 2). Among these, 34 of 43 (79%) had no major underlying conditions, 20 (47%) met criteria for MIS-C, and 3 (7%) had a preexisting neurologic disorder. Life-threatening neurologic conditions included severe encephalopathy (*n* = 15; 5 with white-matter hyperintensities and splenic lesions), acute ischemic or hemorrhagic stroke (*n* = 12), acute CNS infection/ADEM (*n* = 8), acute fulminant cerebral edema (*n* = 4), and GBS (*n* = 4) (Table 2; eTable 2 in Supplement 1). Eight patients with stroke had underlying risk factors (5 experienced stroke during ECMO [eTable 3 in Supplement 1]; 2 were attributed to possible COVID-19-related exacerbation of an underlying primary neurologic disorder [eg, arteriovenous malformation rupture and ischemic stroke in a patient with history of moyamoya syndrome]; and a previously healthy patient presented with a new diagnosis of acute myelogenous leukemia). Four patients were previously healthy and did not have stroke risk factors (eTable 4 in Supplement 1). Five children with severe encephalopathy had brain MRI findings of diffuse white-matter hyperintensities on T2-weighted images and restricted diffusion in the periventricular white matter, deep white matter, and/or corpus callosum (60% with MIS-C; 3 of 5 with unfavorable neurologic outcomes). Representative CNS images from patients with life-threatening neurologic involvement associated with COVID-19 are shown in Figure 2 and Figure 3.

Compared with those with non-life-threatening neurologic involvement, children with life-threatening neurologic disease were more likely to undergo lumbar puncture (20 of 43 [47%] vs 72 of 322 [22%]), head computed tomography (23 of 43 [53%] vs 40 of 322 [12%]) or brain MRI (26 of 43 [60%] vs 28 of 322 [9%]). The cerebrospinal fluid results showed unremarkable findings in both groups (eTable 5 in Supplement 1). As shown in Figure 1B, patients with life-threatening neurologic conditions were more inflamed and coagulopathic than those with no or non-life-threatening neurologic involvement. Patients with life-threatening vs non-life-threatening neurologic involvement had higher neutrophil-to-lymphocyte ratios (median, 12.2 vs 4.4), and higher reported frequency of D-dimer >3 $\mu\text{g/mL}$ fibrinogen equivalent units (21 [49%] vs 72 [22%]; to convert D-dimer to nanomoles per liter, multiply by 5.476; Figure 1; eTable 6 in Supplement 1).

In patients who developed life-threatening neurologic involvement, 11 (26%) died and 17 (40%) were discharged from hospital with new neurologic deficits (Table 2). Of survivors with new deficits, 16 (94%) were previously healthy, none had prior neurologic disorders, 7 (41%) met MIS-C criteria, and

Table 1. Characteristics and Outcomes of 1695 Patients (Age <21 Years) Hospitalized for COVID-19–Related Illness by Reported Neurologic Involvement

Clinical characteristics	No. (%)			P value
	All patients (N = 1695)	Neurological involvement		
		Yes (n = 365)	No (n = 1330)	
Male	909 (54)	204 (56)	705 (53)	.36
Female	786 (46)	161 (44)	625 (47)	
Age, median (IQR), y	9.1 (2.4-15.3)	9.2 (2.5-15.6)	9.0 (2.4-15.1)	.94
Race/ethnicity ^a				
Non-Hispanic				
White	311 (18)	83 (23)	228 (17)	.004
Black	442 (26)	108 (30)	334 (25)	
Hispanic or Latino	638 (38)	125 (34)	513 (39)	
Other race, non-Hispanic	111 (7)	21 (6)	90 (7)	
Unknown	216 (13)	31 (8)	185 (14)	
SARS-CoV-2 testing				
RT-PCR performed	1589 (94)	359 (98)	1230 (92)	<.001
Positive RT-PCR result	1248 (74)	298 (82)	950 (71)	<.001
Antibody test performed	672 (40)	140 (38)	532 (40)	.61
Positive antibody test result	589 (35)	121 (33)	468 (35)	.51
Underlying condition ^b				
Previously healthy ^c	918 (54)	195 (53)	723 (54)	.80
≥1 Comorbidity, excluding obesity	714 (42)	156 (43)	558 (42)	.83
Neurological, any condition				
Seizure disorder	100 (6)	57 (16)	43 (3)	<.001
Neuromuscular disorders ^d	59 (3)	25 (7)	34 (3)	<.001
Autism or developmental delay	42 (2)	18 (5)	24 (2)	.001
Static encephalopathy	40 (2)	18 (5)	22 (2)	<.001
Congenital neurologic disorders ^e	35 (2)	16 (4)	19 (1)	<.001
Prior stroke/HIE	15 (1)	6 (2)	9 (1)	.11
Respiratory				
Cardiac	110 (6)	25 (7)	85 (6)	.85
Gastrointestinal				
Oncologic or immune compromised	122 (7)	17 (5)	105 (8)	.04
Hematological				
Kidney	88 (5)	17 (5)	71 (5)	.70
Endocrine				
Genetic or metabolic (not obesity)	72 (4)	13 (4)	59 (4)	.56
Clinically diagnosed obesity ^f				
Endocrine	129 (8)	25 (7)	104 (8)	.61
Genetic or metabolic (not obesity)				
Clinically diagnosed obesity ^f	69 (4)	23 (6)	46 (3)	.02
Non-CNS organ system involvement				
Met MIS-C criteria	616 (36)	126 (35)	490 (37)	.45
Other organ systems involved				
None	182 (11)	36 (10)	146 (11)	.61
1	341 (20)	74 (20)	267 (20)	.99
2	319 (19)	64 (18)	255 (19)	.53
3	286 (17)	56 (15)	230 (17)	.42
4	567 (34)	135 (37)	432 (33)	.12

(continued)

Table 1. Characteristics and Outcomes of 1695 Patients (Age <21 Years) Hospitalized for COVID-19–Related Illness by Reported Neurologic Involvement (continued)

Clinical characteristics	No. (%)			P value
	All patients (N = 1695)	Neurological involvement		
		Yes (n = 365)	No (n = 1330)	
Outcomes				
ICU	836 (49)	227 (62)	609 (46)	<.001
ECMO	32 (2)	16 (4)	18 (1)	<.001
Mechanical ventilation	225 (13)	103 (28)	122 (9)	<.001
Length of stay, median (IQR), d				
ICU	4 (2-7)	4 (2-9)	4 (2-6)	.02
Hospital	5 (2-9)	5 (2-11)	5 (2-8)	.004
Died	22 (1)	14 (4)	8 (1)	<.001
Survived, new neurological deficit	22 (1)	20 (5)	2 (0.2)	.02
Discharged to rehabilitation	25 (1)	13 (4)	12 (1)	<.001

Abbreviations: CNS, central nervous system; COVID-19, coronavirus disease 2019; ECMO, extracorporeal membrane oxygenation; HIE, hypoxic ischemic encephalopathy; ICU, intensive care unit; IQR, interquartile range; MIS-C, multisystem inflammatory syndrome in children; RT-PCR, reverse transcriptase–polymerase chain reaction; SARS-CoV-2, severe acute respiratory syndrome coronavirus 2.

^a Race and ethnic group were reported by the patient or by the patient's parent or guardian. Race/ethnicity categories are not mutually exclusive.

^b Patients may have more than 1 underlying condition.

^c Previously healthy was defined as an absence of reported underlying

conditions and taking no prescription medications.

^d Neuromuscular disorders include spastic quadriplegia, muscular dystrophy, neuromuscular weakness, and neuromuscular scoliosis.

^e Congenital neurologic disorders include hydrocephalus, neurogenetic, and neurometabolic disorders.

^f The determination of clinically diagnosed obesity was based on reporting by clinicians among patients who were aged at least 2 years (n = 278 for patients with neurological involvements and n = 1017 for patients without neurological involvement).

14 (82%) required rehabilitative services on discharge (eTable 2 in Supplement 1).

Association of COVID-19 Neurologic Involvement With Fatality

Fourteen patients with COVID-19 neurologic involvement died in the hospital. Three deaths were associated with acute COVID-19 cardiorespiratory disease. Two patients with asthma had cardiac arrest on hospital presentation, and 1 previously healthy teenager with anosmia/ageusia died of multiorgan failure. These patients were excluded from further evaluation. The other 11 deaths were classified by expert consensus as either directly associated with COVID-19 neurologic involvement or with catastrophic neurologic events secondary to COVID-19-related critical illness (Table 2). These cases are briefly summarized below (eTable 2 in Supplement 1).

Three previously healthy children with acute fulminant cerebral edema died within 48 hours of hospital admission (eTable 7 in Supplement 1). One male infant with COVID-19 presented with fever, seizures, and gastrointestinal symptoms and within 24 hours of hospitalization developed status epilepticus and had a cardiac arrest, with subsequent imaging showing global cerebral edema. One elementary school-aged girl presented with fever and sore throat, then developed status epilepticus with subsequent imaging revealing cerebral edema with tonsillar herniation. One elementary school-aged boy met criteria for MIS-C 1 month after a positive SARS-CoV-2 respiratory test result. He developed status epilepticus shortly after hospital admission and imaging showed global cerebral edema and uncal herniation.

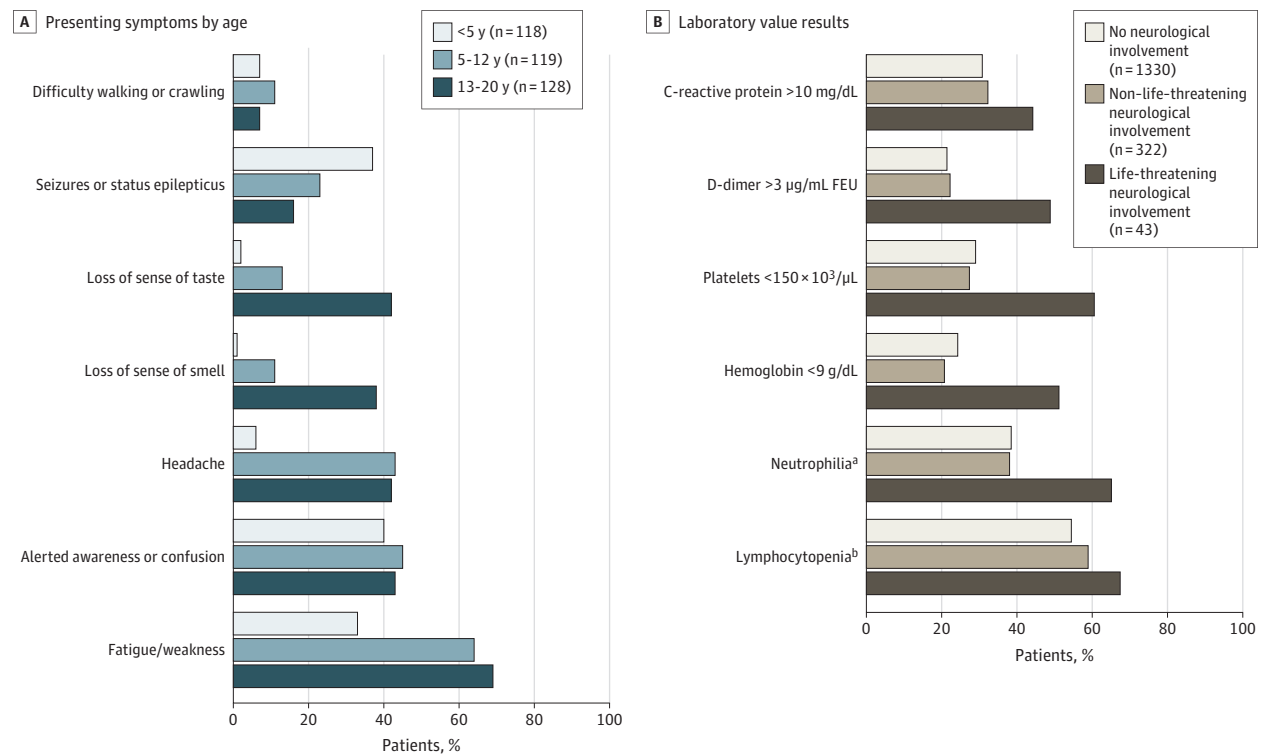
Four patients with stroke died. Three of these patients had strokes with malignant edema and examinations consistent with brain death on ECMO. The fourth died of multiple ischemic strokes owing to rapidly progressive large-vessel CNS vasculitis despite intensive immunotherapies.

Four patients who developed severe encephalopathy died. One immunocompromised adolescent with leukemia and acute COVID-19 pneumonia had diffuse T2 prolongation and reduced diffusivity in the bilateral periventricular white matter, with involvement of the splenium and genu of the corpus callosum, who also developed acute motor-sensory axonal neuropathy confirmed by electromyography/nerve conduction study. Two other patients who died required intubation for severe encephalopathy, complicated by cardiovascular collapse with cannulation for venoarterial ECMO and progression to brain death. One teenager with obesity who died had preexisting hypertension and diabetes and received venoarterial ECMO for cardiorespiratory failure. A brain MRI on decannulation obtained for prolonged encephalopathy showed multifocal areas of restricted diffusion and hemorrhage throughout the posterior white matter and brainstem.

Discussion

In a large, multicenter case series of US children and adolescents hospitalized with acute COVID-19 or MIS-C, 22% of reported patients had neurologic involvement. Approximately half of patients with and without neurologic involvement were previously healthy, a similar percentage had MIS-C, but more

Figure 1. Presenting Neurologic Symptoms and Most Abnormal Laboratory Values in Patients (Age <21 Years) Hospitalized for Coronavirus Disease 2019 (COVID-19)



A, Presenting neurologic symptoms by age in 365 patients (age <21 years) with COVID-19–related neurologic involvement. B, Most abnormal laboratory results in 1695 patients (age <21 years) with COVID-19 by severity of neurologic involvement. Denominators varied and are provided in eTable 6 in Supplement 1. FEU indicates fibrinogen equivalent units.

SI conversion factors: To convert C-reactive protein to mg/L, multiply by 10; D-dimer to nmol/L, multiply by 5.476; hemoglobin to d/L, multiply by 10;

platelet count to ×10⁹/L, multiply by 1.

^a Neutrophilia was defined as a maximum absolute neutrophil count higher than 7700/µL.

^b Lymphocytopenia was defined as an absolute lymphocyte count of less than 1500/µL in patients 8 months or older and of less than 4500/µL in patients younger than 8 months.

patients with neurologic involvement had underlying neurologic disorders (22% vs 8%). Neurologic involvement in most patients was transient and resolved by hospital discharge; however, 43 patients (12%) developed a range of life-threatening neurologic conditions associated with COVID-19, and 66% of these patients had unfavorable outcomes, including death or new neurologic disability at hospital discharge.

The range of neurologic symptoms associated with COVID-19 in children and adolescents was broad and varied by age including seizures/status epilepticus in the younger patients and reports of anosmia and/or ageusia, headache, and fatigue/weakness in older patients. Approximately 1 in 4 patients with neurologic involvement across age groups presented with altered awareness or confusion. The range of severe neurologic complications including peripheral nerve disorders (GBS and variants), focal CNS disease (ischemic stroke due to large vessel occlusion, cerebral venous sinus thrombosis, and focal cerebral arteriopathy), and diffuse CNS involvement (CNS infection, ADEM, severe encephalopathy with white matter and corpus callosum lesions, and acute fulminant cerebral edema) make it likely that multiple mechanisms underlie this wide spectrum of disease. These include putative

mechanisms such as neuroinvasive or neurotropic (direct viral entry and/or neuronal infection via angiotensin-converting enzyme 2^{53,54} and/or olfactory tract^{55,56}), neuro-inflammatory (exaggerated cytokine/immune mediated response leading to blood brain barrier breakdown^{57,58}), postinfectious immune dysregulation,^{59,60} and/or as secondary injury from complications of systemic inflammation or other non-CNS organ failure.⁶¹

We observed 4 cases of GBS that presented with classic neurologic signs, symptoms, and electrophysiologic features within 1 month following SARS-CoV-2 exposure, similar to reports in adults and children in association with COVID-19,^{26,27} and 1 case of acute motor-sensory axonal neuropathy. Animal models and clinicopathological evidence support an autoimmune mechanism and potential molecular mimicry between antibodies against myelin and gangliosides in the nervous system and recent infectious agents, now including COVID-19 infection,^{62,63} and suggests a potential role for anti-ganglioside antibodies in immunomodulatory therapies.

We report 12 cases of acute ischemic or hemorrhagic stroke, with 8 having underlying stroke risk factors. Five of these cases occurred while receiving ECMO, but were included because

Table 2. Life-threatening COVID-19-Related Neurologic Conditions and Deaths in 43 Patients (Age <21 Years) Hospitalized for COVID-19

Variable	Life-threatening COVID-19-related neurologic conditions, No. (%)					
	Overall	Severe encephalopathy	Ischemic or hemorrhagic stroke	Acute CNS infection or ADEM	Acute fulminant cerebral edema	Guillain-Barré syndrome
No.	43	15	12	8	4	4
Age, median (IQR), y ^a		1 Infant	1 Preschooler	1 Infant	1 Infant	2 School aged
		1 Toddler	5 School-aged	1 Toddler	1 Preschooler	2 Adolescents
	12 (7-15)	2 Preschoolers	5 Adolescents	2 Preschoolers	2 School-aged	NA
		5 School-aged	1 Young adult	1 School-aged	NA	NA
		6 Adolescents	NA	3 Adolescents	NA	NA
Male	27 (63)	11 (73)	6 (50)	4 (50)	2 (50)	4 (100)
RT-PCR or antibody results						
Positive RT-PCR result only	19 (44)	7 (47)	7 (58)	2 (25)	3 (75)	0
Positive antibody result only	11 (26)	3 (20)	3 (25)	3 (38)	0	2 (50)
Positive RT-PCR and antibody results	13 (30)	5 (33)	2 (17)	3 (38)	1 (25)	2 (50)
MIS-C diagnosis	20 (47)	8 (53)	3 (25)	6 (75)	2 (50)	1 (25)
No major underlying conditions	34 (79)	11 (73)	8 (67)	8 (100)	4 (100)	3 (75)
Underlying neurologic disorder	3 (7)	1 (7)	2 (17)	0	0	0
Death	11 (26)	4 (27)	4 (33)	0	3 (75)	0
Discharged alive, new CNS deficit	17 (40)	2 (13)	7 (58)	5 (63)	0	3 (75)

Abbreviations: ADEM, acute disseminated encephalomyelitis; CNS, central nervous system; COVID-19, coronavirus disease 2019; IQR, interquartile range; MIS-C, multisystem inflammatory syndrome in children; NA, not applicable; RT-PCR, reverse transcriptase–polymerase chain reaction.

^a Age categories reported for privacy reasons for subcategories of complications: infant (age <1 year), toddler (age 1-2 years), preschool (age 3-5 years), school-aged (age 6-12 years), adolescent (age 13-17 years), and young adult (age 18-21 years).

COVID-19 may have exacerbated an underlying pathophysiologic state (eg, hypercoagulability, hyperinflammation, increased risk of bleeding, and endothelial dysfunction) predisposing to stroke while receiving ECMO.^{64,65} The 4 cases without stroke risk factors were directly associated with COVID-19. In the pediatric literature consisting of case reports and 2 international case series, ischemic stroke type has been reported in 18 children with COVID-19 with stroke mechanisms similar to those observed in our study.^{44,66-69} Acute ischemic stroke in hospitalized adults with COVID-19 is not uncommon.^{8,33,70}

We also describe global cerebral involvement in 15 patients (8 with MIS-C) with severe encephalopathy, 8 patients with acute CNS infection (encephalitis, aseptic meningitis) or postinfectious, central demyelination (ADEM), and 4 patients with acute fulminant cerebral edema. We identified 5 previously healthy patients who presented with severe encephalopathy, focal neurologic deficits, and visual hallucinations (4 of 5 cases) and had diffuse abnormal T2 hyperintensities and reduced diffusivity involving the white matter and genu or splenium of the corpus callosum on MRI. These imaging features have been ascribed to COVID-19 in adults^{50,71} and in children with MIS-C.^{44,51,52} Cytotoxic lesions in the corpus callosum are thought to be associated with increased numbers of glutamate and cytokine receptors in the corpus callosum, particularly the splenium.^{44,72,73} Similar to the range of outcomes in 1 small adult case series,⁵⁰ 3 patients had unfavorable outcomes (1 died and 2 were discharged with new deficits including cognitive impairment and painful

neuropathy requiring gabapentin). Of those with acute CNS infections/ADEM, 7 patients in our study could be confirmed as having probable acute CNS infection using published case definitions.^{48,49} Case reports and small case series also support a link between meningoencephalitis and COVID-19 in adults⁷⁴⁻⁷⁶ and children.^{44,77-79}

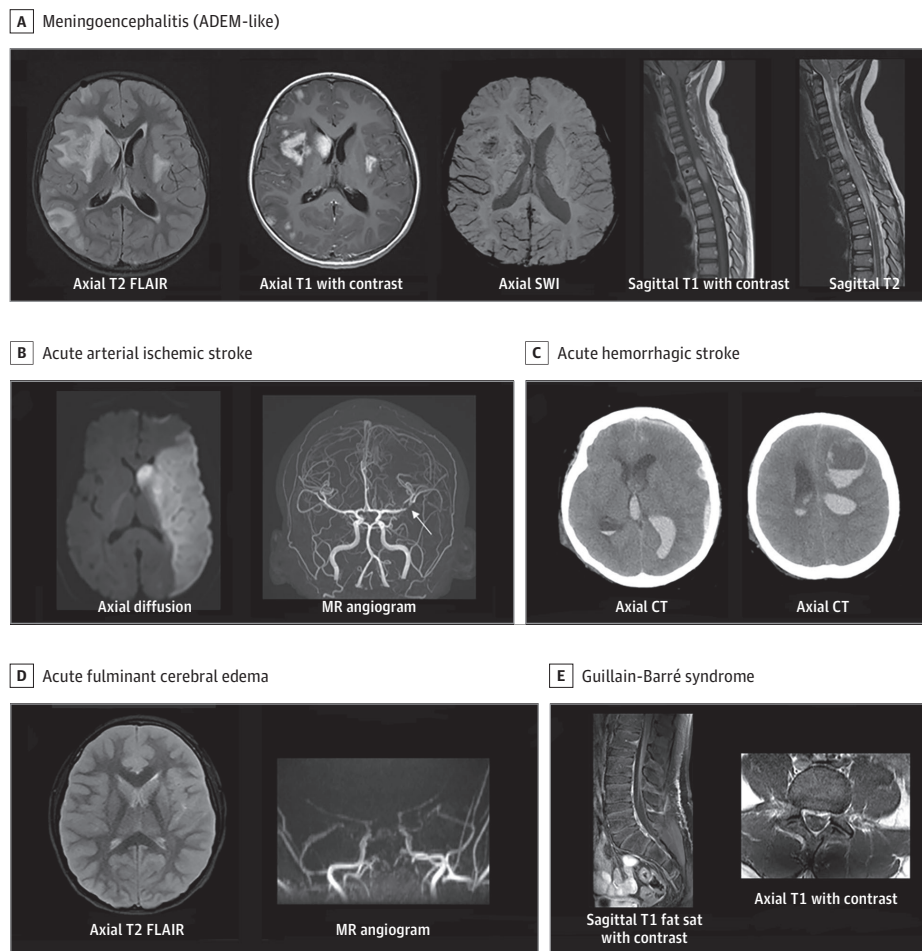
There were 4 cases of previously healthy children who developed acute fulminant cerebral edema directly associated with COVID-19 or MIS-C, and 3 died. Acute fulminant cerebral edema has been previously reported in a child with COVID-19⁸⁰ and is a recognized phenotype with high mortality in adults^{81,82} and children^{44,83} associated with other viral causes.

Our study has several strengths. There was expert adjudication of cases with fatal and life-threatening neurological involvement and new neurologic deficits by pediatric neurology, pediatric critical care, and pediatric neuroradiology experts. The central study team also had personal communication with site clinicians contributing cases with fatal and life-threatening neurologic involvement or new neurologic deficits to confirm diagnoses and clinical course. Neuroimaging was associated with clinical information to document supportive imaging findings and confirm diagnoses. We also captured patients across most US states from a large number of pediatric centers.

Limitations

The study has certain limitations. First, cases of COVID-19-related neurologic involvement were identified only at report-

Figure 2. Representative Central Nervous System Images From Patients With Life-threatening COVID-19–Related Neurologic Involvement



A, Young boy with headache, fatigue, and weakness. Enhancing cerebral lesions with basal ganglia punctate blood products, and abnormal spinal cord signal with focal nodular enhancement. **B**, Male adolescent with right-sided hemiparesis, confusion, and conjunctivitis. Left middle cerebral artery infarct with middle cerebral artery bifurcation intraluminal thrombus (arrow). **C**, Adolescent with cerebral palsy in acute hypoxic respiratory/kidney failure. During recovery sudden respiratory decompensation and shock requiring venovenous extracorporeal membrane oxygenation for 3 to 4 weeks. Computed tomography (CT) for mental status change and anisocoria shows intraventricular,

subdural, and frontal intraparenchymal hemorrhage. **D**, Acute fulminant cerebral edema. Young girl with altered awareness, seizure, nausea, vomiting, acute respiratory failure, and shock requiring vasopressors. Severe cerebral edema with reduced diffusivity and magnetic resonance (MR) angiography with little flow above the level of the supraclinoid internal carotid arteries consistent with brain death. **E**, Adolescent presents with lethargy, paresthesia, and extremity weakness. There are enhancing cauda equina nerve roots. COVID-19 indicates coronavirus disease 2019; fat sat, fat saturation; FLAIR, fluid-attenuated inversion recovery; SWI, susceptibility weighted imaging.

ing hospitals and may not accurately reflect the true range and severity of COVID-19 neurologic involvement. Second, in patients with underlying neurologic diseases, neurologic presentations may be owing to COVID-19 neurologic effects or exacerbation of underlying neurologic conditions. Third, not all patients underwent neuroimaging (possibly owing to infection control concerns or critical illness-related instability) and image acquisition was not standardized, which could result in misclassification or an underestimation of neurologic involvement. Fourth, although standardized case report forms were used, we may not have captured certain variables completely, such as the indications for procedures (eg, lumbar puncture and imaging). Fifth, some neurologic symptoms (eg, anosmia or ageusia) may be underreported in very young patients. Sixth, nonstandardized diagnostic workups performed un-

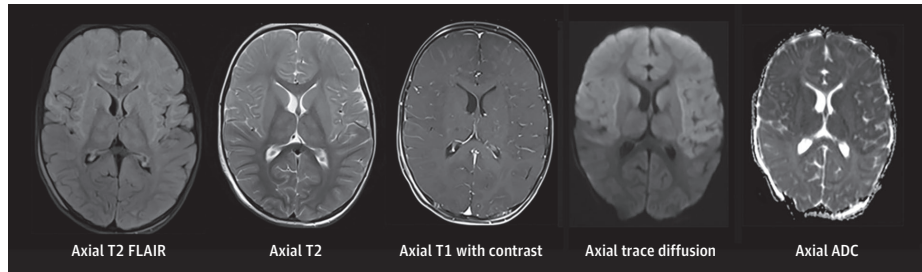
der routine clinical conditions may have missed non-COVID-19-related causes of life-threatening neurological conditions attributed to COVID-19. Seventh, standardized and validated assessments of neurologic outcomes at or after hospital discharge were not performed, likely underestimating the nature and extent of neurologic sequelae. Eighth, this is not a prospective cohort study but a case series, and caution is warranted in interpreting these data to identify risk factors for neurologic involvement.

Conclusions

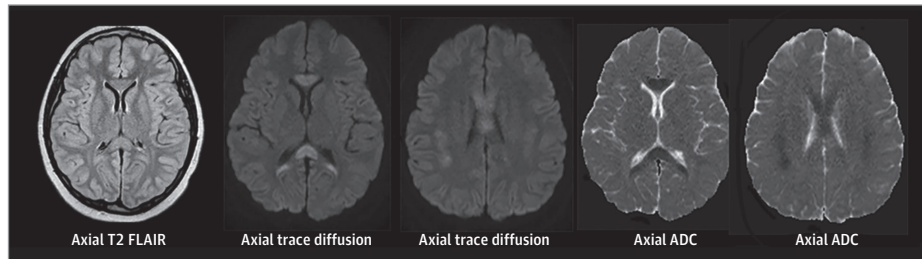
In this study, neurologic involvement was common in children and adolescents with COVID-19-related hospitalization

Figure 3. Representative Central Nervous System Images From Patients With Life-Threatening COVID-19-Related Neurologic Involvement

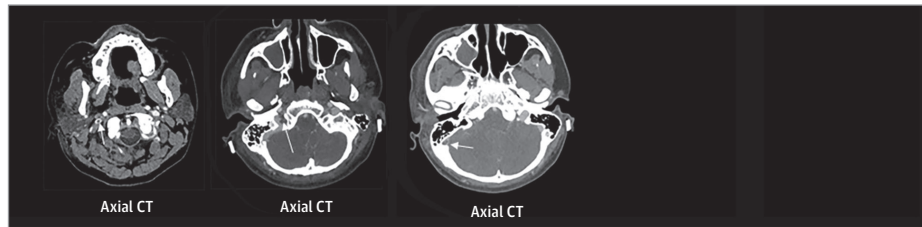
A Encephalitis



B Severe encephalopathy



C Cerebral venous sinus thrombosis



A, Previously healthy toddler with multisystem inflammatory syndrome in children (Ab+) with fever, rash, fatigue, vomiting, decreased oral intake, compensated cardiogenic shock, and generalized tonic-clonic status epilepticus. There is diffuse T2 hyperintensity, leptomeningeal enhancement, and reduced diffusivity within the bilateral frontal lobes, basal ganglia, and thalami. B, School-aged child with coronavirus disease 2019 (COVID-19) and multisystem inflammatory syndrome in children presented with fever, headache, neck pain, abdominal pain, encephalopathy, and visual hallucinations. T2 prolongation with reduced diffusivity in the genu and splenium of corpus callosum, periventricular, and parietal white matter. C, Previously healthy teenager with fever, vomiting, diarrhea, headache, and fatigue presented with altered mental status, visual hallucinations, left hemiparesis, septic shock, and respiratory distress requiring intubation. Axial computed tomography (CT) images demonstrate nonocclusive thrombus in the right internal jugular vein within the upper neck, jugular bulb, and right sigmoid sinus. ADC indicates apparent diffusion coefficient map; FLAIR, fluid-attenuated inversion recovery.

and is mostly transient. A spectrum of life-threatening neurologic involvement infrequently occurred and was associated with more extreme inflammation and severe sequelae. Future immunologic studies of cell-mediated and cytokine immune responses in young individuals may provide insight

into the pathogenesis of neurologic disease in COVID-19 and MIS-C.⁸⁴ Patients with less severe neurologic involvement could have future sequelae. Long-term follow-up of pediatric patients with COVID-19-related neurologic involvement is needed to evaluate effects on cognition and development.

ARTICLE INFORMATION

Accepted for Publication: February 12, 2021.

Published Online: March 5, 2021.

doi:10.1001/jamaneurol.2021.0504

Author Affiliations: Department of Neurology, Boston Children's Hospital, Boston, Massachusetts (LaRovere); Division of Pediatric Anesthesiology and Critical Care Medicine, Department of Anesthesiology and Critical Care Medicine, Johns Hopkins School of Medicine, Baltimore, Maryland (Riggs); Department of Radiology, Boston Children's Hospital, Boston, Massachusetts (Poussaint); Division of Critical Care Medicine, Department of Anesthesiology, Critical Care and Pain Medicine, Boston Children's Hospital, Boston, Massachusetts (Young, Newhams, Randolph); Division of Critical Care Medicine, Department of Pediatrics, University of Texas Southwestern, Children's Health Medical Center Dallas (Maamari);

Department of Pediatrics, University of North Carolina at Chapel Hill Children's Hospital, Chapel Hill (Walker); Pediatric Critical Care Division, Maria Fareri Children's Hospital at Westchester Medical Center and New York Medical College, Valhalla (Singh); Division of Pediatric Critical Care Medicine, Department of Pediatrics, New York University Grossman School of Medicine, New York (Dapul); Division of Infectious Diseases, Department of Pediatrics, Department of Microbiology, University of Mississippi Medical Center, Jackson (Hobbs); Division of Pediatric Critical Care Medicine, Department of Pediatrics, University of Miami Miller School of Medicine, Miami, Florida (McLaughlin); Division of Immunology, Department of Pediatrics, Boston Children's Hospital, Boston, Massachusetts (Son); Section of Critical Care Medicine, Department of Pediatrics, University of Colorado School of Medicine and Children's Hospital Colorado, Aurora (Maddux); Department of

Pediatrics, Joseph M. Sanzari Children's Hospital at Hackensack University Medical Center, Hackensack, New Jersey (Clouser); Division of Pediatric Critical Care Medicine, Department of Pediatrics, Indiana University School of Medicine, Riley Hospital for Children, Indianapolis (Rowan); Division of Pediatric Critical Care Medicine, Department of Pediatrics, University of Washington, Seattle (McGuire); Division of Critical Care, Department of Anesthesiology and Critical Care, University of Pennsylvania Perelman School of Medicine, Philadelphia (Fitzgerald); Division of Pediatric Critical Care, Department of Pediatrics, Saint Barnabas Medical Center, Livingston, New Jersey (Gertz); Division of Pediatric Critical Care Medicine, Rainbow Babies and Children's Hospital, Cleveland, Ohio (Shein); Pediatric Critical Care Division, Department of Pediatrics, University of Texas Health Science Center at Houston, Houston (Munoz); Department of Pediatrics, Penn State

Hershey Children's Hospital, Pennsylvania State University College of Medicine, Hershey (Thomas); Section of Pediatric Critical Care, Department of Pediatrics, Arkansas Children's Hospital, Little Rock (Irby); Divisions of Pediatric Infectious Diseases and Pediatric Critical Care Medicine, Department of Pediatric and Adolescent Medicine, Mayo Clinic, Rochester, Minnesota (Levy); Department of Pediatrics, University of Cincinnati, Division of Infectious Diseases, Cincinnati Children's Hospital Medical Center, Cincinnati, Ohio (Staat); COVID-19 Response, Centers for Disease Control and Prevention, Atlanta, Georgia (Tenforde, Feldstein, Patel); Influenza Division, Centers for Disease Control and Prevention, Atlanta, Georgia (Tenforde, Feldstein, Patel); Division of Pediatric Infectious Diseases, Department of Pediatrics, Vanderbilt University Medical Center, Nashville, Tennessee (Halasa); Division of Critical Care, Yale University School of Medicine, New Haven, Connecticut (Giuliano); Division of Critical Care Medicine, Department of Pediatrics, Nationwide Children's Hospital, Columbus, Ohio (Hall); Division of Pediatric Critical Care Medicine, Department of Pediatrics, University of Alabama at Birmingham (Kong); Division of Critical Care, Connecticut Children's, Hartford, Connecticut (Carroll); Division of Pediatric Infectious Diseases, Department of Pediatrics, Children's Mercy Kansas City, Kansas City, Missouri (Schuster); Division of Pediatric Critical Care, Department of Pediatrics, State University of New York Downstate Health Sciences University, Brooklyn (Doymaz); Section of Critical Care Medicine, Department of Pediatrics, Texas Children's Hospital, Houston (Loftis); Division of Critical Care Medicine, Department of Pediatrics, Emory University School of Medicine, Atlanta, Georgia (Tarquinio); Miller Children's and Women's Hospital of Long Beach, Long Beach, California (Babbitt); Division of Critical Care Medicine, Akron Children's Hospital, Akron, Ohio (Nofziger); Division of Population Health, Quality, and Implementation Sciences (PopQuIS), Department of Pediatrics, Rutgers Robert Wood Johnson Medical School, New Brunswick, New Jersey (Kleinman); Pediatric Critical Care, New York City Health and Hospitals, Kings County Hospital, Brooklyn, New York (Keenaghan); Division of Critical Care Medicine, University of California, San Francisco, Benioff Children's Hospital, Oakland (Cvijanovich); Division of Critical Care, Department of Pediatrics, Washington University School of Medicine in St Louis, St Louis, Missouri (Spinella); Division of Pediatric Critical Care, University of Minnesota Masonic Children's Hospital, Minneapolis (Hume); Division of Pediatric Critical Care, Stead Family Department of Pediatrics, University of Iowa Carver College of Medicine, Iowa City, Iowa (Wellnitz); Division of Pediatric Critical Care Medicine, Medical University of South Carolina, Charleston (Mack); Division of Critical Care Medicine, Department of Pediatrics, Northwestern University Feinberg School of Medicine, Ann and Robert H. Lurie Children's Hospital of Chicago, Chicago, Illinois (Michelson); Division of Pediatric Critical Care Medicine, Department of Pediatrics, Mott Children's Hospital and University of Michigan, Ann Arbor (Flori); Departments of Anaesthesia and Pediatrics, Harvard Medical School, Boston, Massachusetts (Randolph).

Author Contributions: Dr Randolph had full access to all the data in the study and takes responsibility for the integrity of the data and the accuracy of the

data analysis. Drs LaRovere, Riggs, and Poussaint contributed equally. Drs Patel and Randolph contributed equally.

Concept and design: LaRovere, Walker, Hobbs, Feldstein, Doymaz, Spinella, Patel, Randolph. **Acquisition, analysis, or interpretation of data:** LaRovere, Riggs, Poussaint, Young, Newhams, Maamari, Singh, Dapul, Hobbs, McLaughlin, Son, Maddux, Clouser, Rowan, McGuire, Fitzgerald, Gertz, Shein, Coronado Munoz, Thomas, Irby, Levy, Staat, Tenforde, Halasa, Giuliano, Hall, Kong, Carroll, Schuster, Loftis, Tarquinio, Babbitt, Nofziger, Kleinman, Keenaghan, Cvijanovich, Spinella, Hume, Wellnitz, Mack, Michelson, Flori, Patel, Randolph.

Drafting of the manuscript: LaRovere, Riggs, Poussaint, Hobbs, Kong, Spinella, Randolph.

Critical revision of the manuscript for important intellectual content: All authors.

Statistical analysis: LaRovere, Giuliano, Randolph. **Obtained funding:** Randolph.

Administrative, technical, or material support: Poussaint, Newhams, Maamari, Singh, Hobbs, McLaughlin, Son, Rowan, Fitzgerald, Gertz, Shein, Coronado Munoz, Levy, Tenforde, Feldstein, Hall, Kong, Carroll, Schuster, Doymaz, Loftis, Babbitt, Nofziger, Cvijanovich, Spinella, Hume, Wellnitz, Michelson, Flori, Patel, Randolph. **Supervision:** Newhams, Walker, Singh, Hobbs, McLaughlin, Thomas, Irby, Staat, Kong, Schuster, Loftis, Nofziger, Cvijanovich, Spinella, Hume, Patel, Randolph.

Conflict of Interest Disclosures: Dr Riggs reported grants from the US Centers for Disease Control and Prevention (CDC) funding through Boston Children's Hospital during the conduct of the study. Dr Newhams reported grants from the CDC during the conduct of the study. Dr Maamari reported other support from the CDC during the conduct of the study. Dr McLaughlin reported grants from Boston Children's Hospital and the CDC during the conduct of the study. Dr Maddux reported grants from the National Institutes of Health (NIH)/Eunice Kennedy Shriver National Institute of Child Health and Human Development during the conduct of the study. Dr Rowan reported grants from the CDC during the conduct of the study and from the NIH outside the submitted work. Dr McGuire reported grants from the CDC during the conduct of the study. Dr Fitzgerald reported grants from the CDC during the conduct of the study and from the NIH outside the submitted work. Dr Gertz reported grants from Boston Children's Hospital as a passthrough for the CDC during the conduct of the study. Dr Shein reported grants from the CDC during the conduct of the study. Dr Coronado Munoz reported grants from the CDC during the conduct of the study. Dr Levy reported grants from the CDC during the conduct of the study and from the National Institute of Allergy and Infectious Diseases outside the submitted work. Dr Staat reported other support from Boston Children's Hospital during the conduct of the study. Dr Halasa reported grants from the CDC during the conduct of the study; grants from Sanofi and Quidel; and personal fees from Genentech outside the submitted work. Dr Hall reported grants from the CDC during the conduct of the study and personal fees from LaJolla Pharmaceuticals outside the submitted work. Dr Schuster reported other from the CDC during the conduct of the study; other support from Merck; and grants from the CDC outside the submitted work. Dr Doymaz reported

grants from the CDC during the conduct of the study. Dr Tarquinio reported grants from the CDC during the conduct of the study. Dr Nofziger reported other from the CDC during the conduct of the study. Dr Kleinman reported grants from Boston Children's Hospital during the conduct of the study and grants from Health Services Research Administration and NICHHD outside the submitted work. Dr Cvijanovich reported grants from the CDC during the conduct of the study and grants from Cincinnati Children's Medical Center and Boston Children's Hospital outside the submitted work. Dr Hume reported grants from the CDC during the conduct of the study. Dr Wellnitz reported other support from the CDC and NIH during the conduct of the study. Dr Michelson reported grants from the CDC during the conduct of the study and grants National Palliative Care Research Center and the National Institutes of Health outside the submitted work. Dr Randolph reported grants from the CDC during the conduct of the study and other support from UpToDate outside the submitted work. Dr Poussaint reported receiving grants from the National Institutes of Health and royalties from Springer Publishing outside of the submitted work. No other disclosures were reported.

Funding/Support: This study was funded by the US Centers for Disease Control and Prevention under a contract to Boston Children's Hospital.

Role of the Funder/Sponsor: The US Centers for Disease Control and Prevention designed and conducted the study; collected, managed, analyzed, and interpreted the data; prepared, reviewed, and approved the manuscript; had a role in the decision to submit the manuscript for publication and journal choice; and had the right to veto publication.

Disclaimer: The findings and conclusions in this report are those of the authors and do not necessarily represent the official position of the US Centers for Disease Control and Prevention.

Group Information: The Overcoming COVID-19 Investigators are listed in [Supplement 2](#).

Additional Contributions: We appreciate and thank the many research coordinators at the Overcoming COVID-19 hospitals who assisted in data collection for this study. We thank the leadership of the Pediatric Acute Lung Injury and Sepsis Investigator's (PALISI) Network for their ongoing support.

REFERENCES

1. Montalvan V, Lee J, Bueso T, De Toledo J, Rivas K. Neurological manifestations of COVID-19 and other coronavirus infections: a systematic review. *Clin Neurol Neurosurg*. 2020;194:105921. doi:10.1016/j.clineuro.2020.105921
2. Ellul MA, Benjamin L, Singh B, et al. Neurological associations of COVID-19. *Lancet Neurol*. 2020;19(9):767-783. doi:10.1016/S1474-4422(20)30221-0
3. Baig AM. Neurological manifestations in COVID-19 caused by SARS-CoV-2. *CNS Neurosci Ther*. 2020;26(5):499-501. doi:10.1111/cns.13372
4. Paterson RW, Brown RL, Benjamin L, et al. The emerging spectrum of COVID-19 neurology: clinical, radiological and laboratory findings. *Brain*. 2020;143(10):3104-3120. doi:10.1093/brain/awaa240
5. Zubair AS, McAlpine LS, Gardin T, Farhadian S, Kuruvilla DE, Spudich S. Neuropathogenesis and neurologic manifestations of the coronaviruses in

- the age of coronavirus disease 2019: a review. *JAMA Neurol.* 2020;77(8):1018-1027. doi:10.1001/jamaneurol.2020.2065
6. Koralnik IJ, Tyler KL. COVID-19: A global threat to the nervous system. *Ann Neurol.* 2020;88(1):1-11. doi:10.1002/ana.25807
7. Aghagholi G, Gallo Marin B, Katchur NJ, Chaves-Sell F, Asaad WF, Murphy SA. Neurological involvement in COVID-19 and potential mechanisms: a review. *Neurocrit Care.* 2020. doi:10.1007/s12028-020-01049-4
8. Favas TT, Dev P, Chaurasia RN, et al. Neurological manifestations of COVID-19: a systematic review and meta-analysis of proportions. *Neurol Sci.* 2020; 41(12):3437-3470. doi:10.1007/s10072-020-04801-y
9. Stafstrom CE, Jantzie LL. COVID-19: neurological considerations in neonates and children. *Children (Basel).* 2020;7(9):E133. doi:10.3390/children7090133
10. Mao L, Jin H, Wang M, et al. Neurologic manifestations of hospitalized patients with coronavirus disease 2019 in Wuhan, China. *JAMA Neurol.* 2020;77(6):683-690. doi:10.1001/jamaneurol.2020.1127
11. Lechien JR, Chiesa-Estomba CM, De Siati DR, et al. Olfactory and gustatory dysfunctions as a clinical presentation of mild-to-moderate forms of the coronavirus disease (COVID-19): a multicenter European study. *Eur Arch Otorhinolaryngol.* 2020;277(8):2251-2261. doi:10.1007/s00405-020-05965-1
12. Bénézit F, Le Turnier P, Declercq C, et al; RAN COVID Study Group. Utility of hyposmia and hypogeusia for the diagnosis of COVID-19. *Lancet Infect Dis.* 2020;20(9):1014-1015. doi:10.1016/S1473-3099(20)30297-8
13. Bolay H, Gül A, Baykan B. COVID-19 is a real headache. *Headache.* 2020;60(7):1415-1421. doi:10.1111/head.13856
14. Varatharaj A, Thomas N, Ellul MA, et al; CoroNerve Study Group. Neurological and neuropsychiatric complications of COVID-19 in 153 patients: a UK-wide surveillance study. *Lancet Psychiatry.* 2020;7(10):875-882. doi:10.1016/S2215-0366(20)30287-X
15. Moriguchi T, Harii N, Goto J, et al. A first case of meningitis/encephalitis associated with SARS-Coronavirus-2. *Int J Infect Dis.* 2020;94:55-58. doi:10.1016/j.ijid.2020.03.062
16. Helms J, Kremer S, Merdji H, et al. Neurologic features in severe SARS-CoV-2 infection. *N Engl J Med.* 2020;382(23):2268-2270. doi:10.1056/NEJMc2008597
17. Farhadian S, Glick LR, Vogels CBF, et al. Acute encephalopathy with elevated CSF inflammatory markers as the initial presentation of COVID-19. *BMC Neurol.* 2020;20(1):248. doi:10.1186/s12883-020-01812-2
18. Etemadifar M, Salari M, Murgai AA, Hajjahmadi S. Fulminant encephalitis as a sole manifestation of COVID-19. *Neurol Sci.* 2020;41(11):3027-3029. doi:10.1007/s10072-020-04712-y
19. Poyiadji N, Shahin G, Noujaim D, Stone M, Patel S, Griffith B. COVID-19-associated acute hemorrhagic necrotizing encephalopathy: imaging features. *Radiology.* 2020;296(2):E119-E120. doi:10.1148/radiol.2020201187
20. Delamarre L, Gollion C, Grouteau G, et al; NeuroICU Research Group. COVID-19-associated acute necrotizing encephalopathy successfully treated with steroids and polyvalent immunoglobulin with unusual IgG targeting the cerebral fibre network. *J Neurol Neurosurg Psychiatry.* 2020;91(9):1004-1006. doi:10.1136/jnnp-2020-323678
21. Hepburn M, Mullaguri N, George P, et al. Acute symptomatic seizures in critically ill patients with COVID-19: is there an association? *Neurocrit Care.* 2020. doi:10.1007/s12028-020-01006-1
22. Sohal S, Mansur M. COVID-19 presenting with seizures. *IDCases.* 2020;20:e00782. doi:10.1016/j.idcr.2020.e00782
23. AlKetbi R, AlNuaimi D, AlMulla M, et al. Acute myelitis as a neurological complication of Covid-19: a case report and MRI findings. *Radiol Case Rep.* 2020;15(9):1591-1595. doi:10.1016/j.radcr.2020.06.001
24. Valiuddin H, Skwirsk B, Paz-Arabo P. Acute transverse myelitis associated with SARS-CoV-2: a case-report. *Brain Behav Immun Health.* 2020;5:100091. doi:10.1016/j.bbih.2020.100091
25. Chakraborty U, Chandra A, Ray AK, Biswas P. COVID-19-associated acute transverse myelitis: a rare entity. *BMJ Case Rep.* 2020;13(8):e238668. doi:10.1136/bcr-2020-238668
26. Abu-Rumeileh S, Abdelhak A, Foschi M, Tuman H, Otto M. Guillain-Barré syndrome spectrum associated with COVID-19: an up-to-date systematic review of 73 cases. *J Neurol.* 2020. doi:10.1007/s00415-020-10124-x
27. Uncini A, Vallat JM, Jacobs BC. Guillain-Barré syndrome in SARS-CoV-2 infection: an instant systematic review of the first six months of pandemic. *J Neurol Neurosurg Psychiatry.* 2020;91(10):1105-1110. doi:10.1136/jnnp-2020-324491
28. Parauda SC, Gao V, Gewirtz AN, et al. Posterior reversible encephalopathy syndrome in patients with COVID-19. *J Neurol Sci.* 2020;416:117019. doi:10.1016/j.jns.2020.117019
29. Dafer RM, Osteraas ND, Biller J. Acute stroke care in the coronavirus disease 2019 pandemic. *J Stroke Cerebrovasc Dis.* 2020;29(7):104881. doi:10.1016/j.jstrokecerebrovasdis.2020.104881
30. Morassi M, Bagatto D, Cobelli M, et al. Stroke in patients with SARS-CoV-2 infection: case series. *J Neurol.* 2020;267(8):2185-2192. doi:10.1007/s00415-020-09885-2
31. Beyroui R, Adams ME, Benjamin L, et al. Characteristics of ischaemic stroke associated with COVID-19. *J Neurol Neurosurg Psychiatry.* 2020;91(8):889-891. doi:10.1136/jnnp-2020-323586
32. Hughes C, Nichols T, Pike M, Subbe C, Elghenzai S. Cerebral venous sinus thrombosis as a presentation of COVID-19. *Eur J Case Rep Intern Med.* 2020;7(5):001691. doi:10.12890/2020_001691
33. Majidi S, Fifi JT, Ladner TR, et al. Emergent large vessel occlusion stroke during New York City's COVID-19 outbreak: clinical characteristics and paraclinical findings. *Stroke.* 2020;51(9):2656-2663. doi:10.1161/STROKEAHA.120.030397
34. Oxley TJ, Mocco J, Majidi S, et al. Large-vessel stroke as a presenting feature of Covid-19 in the young. *N Engl J Med.* 2020;382(20):e60. doi:10.1056/NEJMc2009787
35. Dufort EM, Koumans EH, Chow EJ, et al; New York State and Centers for Disease Control and Prevention Multisystem Inflammatory Syndrome in Children Investigation Team. Multisystem inflammatory syndrome in children in New York State. *N Engl J Med.* 2020;383(4):347-358. doi:10.1056/NEJMoa2021756
36. Feldstein LR, Rose EB, Horwitz SM, et al; Overcoming COVID-19 Investigators; CDC COVID-19 Response Team. Multisystem inflammatory syndrome in U.S. children and adolescents. *N Engl J Med.* 2020;383(4):334-346. doi:10.1056/NEJMoa2021680
37. Ahmed M, Advani S, Moreira A, et al. Multisystem inflammatory syndrome in children: a systematic review. *EClinicalMedicine.* 2020;26:100527. doi:10.1016/j.eclinm.2020.100527
38. Aronoff SC, Hall A, Del Vecchio MT. The natural history of severe acute respiratory syndrome coronavirus 2-related multisystem inflammatory syndrome in children: a systematic review. *J Pediatric Infect Dis Soc.* 2020;9(6):746-751. doi:10.1093/jpids/piaa112
39. Kaushik A, Gupta S, Sood M, Sharma S, Verma S. A systematic review of multisystem inflammatory syndrome in children associated with SARS-CoV-2 infection. *Pediatr Infect Dis J.* 2020;39(11):e340-e346. doi:10.1097/INF.0000000000002888
40. Abrams JY, Godfred-Cato SE, Oster ME, et al. Multisystem inflammatory syndrome in children associated with severe acute respiratory syndrome coronavirus 2: a systematic review. *J Pediatr.* 2020; S0022-3476(20)30985-9. doi:10.1016/j.jpeds.2020.08.003
41. DeBiasi RL, Song X, Delaney M, et al. Severe coronavirus disease-2019 in children and young adults in the Washington, DC, metropolitan region. *J Pediatr.* 2020;223:199-203.e1. doi:10.1016/j.jpeds.2020.05.007
42. Shekerdemian LS, Mahmood NR, Wolfe KK, et al; International COVID-19 PICU Collaborative. Characteristics and outcomes of children with coronavirus disease 2019 (COVID-19) infection admitted to US and Canadian pediatric intensive care units. *JAMA Pediatr.* 2020;174(9):868-873. doi:10.1001/jamapediatrics.2020.1948
43. Prata-Barbosa A, Lima-Setta F, Santos GRD, et al; Brazilian Research Network in Pediatric Intensive Care. (BRnet-PIC). Pediatric patients with COVID-19 admitted to intensive care units in Brazil: a prospective multicenter study. *J Pediatr (Rio J).* 2020;96(5):582-592. doi:10.1016/j.jpeds.2020.07.002
44. Lindan CE, Mankad K, Ram D, et al; ASPNR PECOBIG Collaborator Group. Neuroimaging manifestations in children with SARS-CoV-2 infection: a multinational, multicentre collaborative study. *Lancet Child Adolesc Health.* 2020;S2352-4642(20)30362-X. doi:10.1016/S2352-4642(20)30362-X
45. Lin JE, Asfour A, Sewell TB, et al. Neurological issues in children with COVID-19. *Neurosci Lett.* 2021;743:135567. doi:10.1016/j.neulet.2020.135567
46. Panda PK, Sharawat IK, Panda P, Natarajan V, Bhakat R, Dawman L. Neurological complications of SARS-CoV-2 infection in children: a systematic review and meta-analysis. *J Trop Pediatr.* 2020; fmaa070. doi:10.1093/tropej/fmaa070

47. Centers for Disease Control and Prevention. Information for healthcare providers about multisystem inflammatory syndrome in children (MIS-C). Accessed December 4, 2020. <https://www.cdc.gov/mis-c/hcp/>
48. Venkatesan A, Tunkel AR, Bloch KC, et al; International Encephalitis Consortium. Case definitions, diagnostic algorithms, and priorities in encephalitis: consensus statement of the international encephalitis consortium. *Clin Infect Dis*. 2013;57(8):1114-1128. doi:10.1093/cid/cit458
49. Sejvar JJ, Kohl KS, Bilynsky R, et al; Brighton Collaboration Encephalitis Working Group. Encephalitis, myelitis, and acute disseminated encephalomyelitis (ADEM): case definitions and guidelines for collection, analysis, and presentation of immunization safety data. *Vaccine*. 2007;25(31):5771-5792. doi:10.1016/j.vaccine.2007.04.060
50. Agarwal S, Conway J, Nguyen V, et al. Serial Imaging of virus-associated necrotizing disseminated acute leukoencephalopathy (VANDAL) in COVID-19. *AJNR Am J Neuroradiol*. 2021;42(2):279-284. doi:10.3174/ajnr.A6898
51. Abdel-Mannan O, Eyre M, Löbel U, et al. Neurologic and radiographic findings associated with COVID-19 infection in children. *JAMA Neurol*. 2020. doi:10.1001/jamaneurol.2020.2687
52. Lin J, Lawson EC, Verma S, Peterson RB, Sidhu R. Cytotoxic lesion of the corpus callosum in an adolescent with multisystem inflammatory syndrome and SARS-CoV-2 infection. *AJNR Am J Neuroradiol*. 2020;41(11):2017-2019. doi:10.3174/ajnr.A6755
53. Baig AM, Khaleeq A, Ali U, Syeda H. Evidence of the COVID-19 virus targeting the CNS: tissue distribution, host-virus interaction, and proposed neurotropic mechanisms. *ACS Chem Neurosci*. 2020;11(7):995-998. doi:10.1021/acscchemneuro.0c00122
54. Guo Y, Korteweg C, McNutt MA, Gu J. Pathogenetic mechanisms of severe acute respiratory syndrome. *Virus Res*. 2008;133(1):4-12. doi:10.1016/j.virusres.2007.01.022
55. van Riel D, Verdijk R, Kuiken T. The olfactory nerve: a shortcut for influenza and other viral diseases into the central nervous system. *J Pathol*. 2015;235(2):277-287. doi:10.1002/path.4461
56. Netland J, Meyerholz DK, Moore S, Cassell M, Perlman S. Severe acute respiratory syndrome coronavirus infection causes neuronal death in the absence of encephalitis in mice transgenic for human ACE2. *J Virol*. 2008;82(15):7264-7275. doi:10.1128/JVI.00737-08
57. Matschke J, Lütgehetmann M, Hagel C, et al. Neuropathology of patients with COVID-19 in Germany: a post-mortem case series. *Lancet Neurol*. 2020;19(11):919-929. doi:10.1016/S1474-4422(20)30308-2
58. Buzhdygan TP, DeOre BJ, Baldwin-Leclair A, et al. The SARS-CoV-2 spike protein alters barrier function in 2D static and 3D microfluidic in vitro models of the human blood-brain barrier. *bioRxiv*. Posted June 15, 2020. doi:10.1101/2020.06.15.150912
59. Alberti P, Beretta S, Piatti M, et al. Guillain-Barré syndrome related to COVID-19 infection. *Neurol Neuroimmunol Neuroinflamm*. 2020;7(4):e741. doi:10.1212/NXI.0000000000000741
60. Dalakas MC. Guillain-Barré syndrome: the first documented COVID-19-triggered autoimmune neurologic disease: more to come with myositis in the offing. *Neurol Neuroimmunol Neuroinflamm*. 2020;7(5):e781. doi:10.1212/NXI.0000000000000781
61. Iadecola C, Anrather J, Kamel H. Effects of COVID-19 on the nervous system. *Cell*. 2020;183(1):16-27.e1. doi:10.1016/j.cell.2020.08.028
62. Yuki N, Hartung HP. Guillain-Barré syndrome. *N Engl J Med*. 2012;366(24):2294-2304. doi:10.1056/NEJMra1114525
63. Kreye J, Reincke SM, Prüss H. Do cross-reactive antibodies cause neuropathology in COVID-19? *Nat Rev Immunol*. 2020;20(11):645-646. doi:10.1038/s41577-020-00458-y
64. Kowalewski M, Fina D, Słomka A, et al. COVID-19 and ECMO: the interplay between coagulation and inflammation—a narrative review. *Crit Care*. 2020;24(1):205. doi:10.1186/s13054-020-02925-3
65. Lax SF, Skok K, Zechner P, et al. Pulmonary arterial thrombosis in COVID-19 with fatal outcome: results from a prospective, single-center, clinicopathologic case series. *Ann Intern Med*. 2020;173(5):350-361. doi:10.7326/M20-2566
66. Beslow LA, Linds AB, Fox CK, et al; International Pediatric Stroke Study Group. Pediatric ischemic stroke: an infrequent complication of SARS-CoV-2. *Ann Neurol*. 2020. doi:10.1002/ana.25991
67. Appavu B, Deng D, Dowling MM, et al. Arteritis and large vessel occlusive strokes in children following COVID-19 infection. *Pediatrics*. 2020; e2020023440. doi:10.1542/peds.2020-023440
68. Gulko E, Overby P, Ali S, Mehta H, Al-Mufti F, Gomes W. Vessel wall enhancement and focal cerebral arteriopathy in a pediatric patient with acute infarct and COVID-19 infection. *AJNR Am J Neuroradiol*. 2020;41(12):2348-2350. doi:10.3174/ajnr.A6778
69. Mirzaee SMM, Gonçalves FG, Mohammadifard M, Tavakoli SM, Vossough A. Focal cerebral arteriopathy in a pediatric patient with COVID-19. *Radiology*. 2020;297(2):E274-E275. doi:10.1148/radiol.2020202197
70. Majmundar N, Ducruet A, Prakash T, Nanda A, Khandelwal P. Incidence, pathophysiology, and impact of coronavirus disease 2019 (COVID-19) on acute ischemic stroke. *World Neurosurg*. 2020;142:523-525. doi:10.1016/j.wneu.2020.07.158
71. Radmanesh A, Derman A, Lui YW, et al. COVID-19-associated diffuse leukoencephalopathy and microhemorrhages. *Radiology*. 2020;297(1):E223-E227. doi:10.1148/radiol.2020202040
72. Rasmussen C, Niculescu I, Patel S, Krishnan A. COVID-19 and involvement of the corpus callosum: potential effect of the cytokine storm? *AJNR Am J Neuroradiol*. 2020;41(9):1625-1628. doi:10.3174/ajnr.A6680
73. Moonis G, Filippi CG, Kirsch CFE, et al. The spectrum of neuroimaging findings on CT and MRI in adults with coronavirus disease (COVID-19). *AJR Am J Roentgenol*. 2020. doi:10.2214/AJR.20.24839
74. Duong L, Xu P, Liu A. Meningoencephalitis without respiratory failure in a young female patient with COVID-19 infection in Downtown Los Angeles, early April 2020. *Brain Behav Immun*. 2020;87:33. doi:10.1016/j.bbi.2020.04.024
75. Bernard-Valnet R, Pizzarotti B, Anichini A, et al. Two patients with acute meningoencephalitis concomitant with SARS-CoV-2 infection. *Eur J Neurol*. 2020;27(9):e43-e44. doi:10.1111/ene.14298
76. Ghannam M, Alsharq Q, Al-Chalabi M, Zakarna L, Robertson J, Manousakis G. Neurological involvement of coronavirus disease 2019: a systematic review. *J Neurol*. 2020;267(11):3135-3153. doi:10.1007/s00415-020-09990-2
77. Morfopoulou S, Brown JR, Davies EG, et al. Human coronavirus OC43 associated with fatal encephalitis. *N Engl J Med*. 2016;375(5):497-498. doi:10.1056/NEJMcl509458
78. Yeh EA, Collins A, Cohen ME, Duffner PK, Faden H. Detection of coronavirus in the central nervous system of a child with acute disseminated encephalomyelitis. *Pediatrics*. 2004;113(1 pt 1):e73-e76. doi:10.1542/peds.113.1.e73
79. Shenker J, Trogen B, Schroeder L, Ratner AJ, Kahn P. Multisystem inflammatory syndrome in children associated with status epilepticus. *J Pediatr*. 2020;227(Jul):300-301. doi:10.1016/j.jpeds.2020.07.062
80. Kim MG, Stein AA, Overby P, et al. Fatal cerebral edema in a child with COVID-19. *Pediatr Neurol*. 2021;114:77-78. doi:10.1016/j.pediatrneurol.2020.10.005
81. Piliero PJ, Brody J, Zamani A, Deresiewicz RL. Eastern equine encephalitis presenting as focal neuroimaging abnormalities: case report and review. *Clin Infect Dis*. 1994;18(6):985-988. doi:10.1093/clinids/18.6.985
82. Wendell LC, Potter NS, Roth JL, Salloway SP, Thompson BB. Successful management of severe neuroinvasive eastern equine encephalitis. *Neurocrit Care*. 2013;19(1):111-115. doi:10.1007/s12028-013-9822-5
83. Krishnan P, Glenn OA, Samuel MC, et al. Acute fulminant cerebral edema: a newly recognized phenotype in children with suspected encephalitis. *J Pediatric Infect Dis Soc*. 2020;pii:063. doi:10.1093/jpids/piaa063
84. Carter MJ, Fish M, Jennings A, et al. Peripheral immunophenotypes in children with multisystem inflammatory syndrome associated with SARS-CoV-2 infection. *Nat Med*. 2020;26(11):1701-1707. doi:10.1038/s41591-020-1054-6